

# Acute Achilles Tendon Rupture in Athletes

Umile Giuseppe Longo, MD, MSc, PhD<sup>a,b,\*</sup>, Stefano Petrillo, MD<sup>a,b</sup>,  
Nicola Maffulli, MD, MS, PhD, FRCS(Orth)<sup>c</sup>, Vincenzo Denaro, MD<sup>a,b</sup>

## KEYWORDS

• Achilles tendon rupture • Operative repair of achilles • Athlete

## KEY POINTS

- Athletes require operative repair of the Achilles tendon following acute rupture.
- The choice of open versus percutaneous techniques continues to be debated.
- Early rehabilitation should be instigated: early movement and weight bearing leads to improved tendon healing.

## INTRODUCTION

The Achilles tendon (AT) is the strongest and largest tendon in the human body, and is also the most frequently ruptured.<sup>1,2</sup> AT rupture is more common in men, with a male/female ratio of between 1.7:1 and 30:1. However, ATs in men present higher stiffness and maximum rupture force than in women, and also have a larger cross-sectional area.<sup>3</sup> Moreover, younger tendons present significantly higher tensile rupture stress despite having lower stiffness.<sup>4</sup> The incidence of AT ruptures has largely increased in the last decade,<sup>5,6</sup> and they usually occur in sedentary, white-collar individuals who play sport occasionally, mostly in the third or fourth decade of life.<sup>7</sup> Therefore, most AT ruptures (44%–83%) occur during sport activities, and biochemical and biomechanical changes related to aging may play a significant role in the pathogenesis of the injury.<sup>8</sup> Subcutaneous tears are more common in the AT compared with any other tendon in human body. Several microscopic interruptions in the tendinous substance occur during normal activities, whereas fibers remodel and new collagen is continuously formed.<sup>9,10</sup> A tendon usually loses its wavy configuration when stretched more than 2%. When the tendon is stretched by more than 3% to 4% of its normal length, it starts to disrupt, and, when stretched more than 8%, macroscopic rupture occurs.<sup>11</sup>

---

<sup>a</sup> Department of Orthopaedic and Trauma Surgery, Campus Bio-Medico University, Via Alvaro del Portillo, 200, Trigatoria, Rome 00128, Italy; <sup>b</sup> Centro Integrato di Ricerca (CIR), Campus Bio-Medico University, Via Alvaro del Portillo, 21, Rome 00128, Italy; <sup>c</sup> Centre for Sports and Exercise Medicine, Barts and The London School of Medicine and Dentistry, Mile End Hospital, 275 Bancroft Road, London E1 4DG, England

\* Corresponding author.

E-mail address: [g.longo@unicampus.it](mailto:g.longo@unicampus.it)

Foot Ankle Clin N Am 18 (2013) 319–338

<http://dx.doi.org/10.1016/j.fcl.2013.02.009>

1083-7515/13/\$ – see front matter © 2013 Elsevier Inc. All rights reserved.

[foot.theclinics.com](http://foot.theclinics.com)

## ANATOMY AND HISTOLOGY

The AT consists of the tendinous portions of the gastrocnemius and soleus muscles. Moreover, the plantaris muscle is present in 93% (752 of 810) of lower extremities, located medially to the AT and distinct from it.<sup>12</sup> The medial and lateral heads of the gastrocnemius originate from the femoral condyles and their contribution to the AT commences as a wide aponeurosis at the lower ends of these muscular bellies.<sup>12</sup> The soleus muscle originates from the tibia and fibula, and its tendinous contribution to the Achilles tendon is shorter and thicker.<sup>12</sup> The calcaneal insertion is composed of a specialized layer of hyaline cartilage and an area of bone not covered by periosteum. A retrocalcaneal bursa is located between the AT and the calcaneus, whereas a subcutaneous bursa is located between the tendon and the skin.<sup>13</sup> The cellular population of the tendon is composed of tenocytes and tenoblasts for 90% to 95%, whereas collagen and elastin proteins account for 70% and 2% of the dry weight of a tendon, respectively, and form most of the extracellular matrix (ECM).<sup>14</sup> Type I collagen is the most common, and it accounts for 95% of tendon collagen,<sup>15</sup> whereas tenocytes from ruptured ATs produce more type III collagen than tenocytes from normal ATs,<sup>16</sup> which is less resistant and elastic to tensile force. The ground substance of ECM surrounding the collagen and the tenocytes is composed of glycoproteins, glycosaminoglycans, and proteoglycans.<sup>17</sup> Glycosaminoglycans decrease with aging, whereas collagen increases, and acute exercise increases the formation of type I collagen in the peritendinous tissue.<sup>18,19</sup> The tendon is formed by well-organized fascicles surrounded by endotenon. These fascicles are enveloped by a layer of connective tissue, the epitenon, in direct contact with the endotenon.<sup>20–22</sup> The epitenon, in turn, is surrounded by the paratenon with a thin layer of fluid in between to allow tendon movement with reduced friction.<sup>23</sup> Type I and type III collagen fibrils, an inner lining of synovial cells, and few elastin fibrils compose the paratenon, which is in contact with the fascia cruris covering the posterior aspect of the tendon.<sup>24</sup> In addition, the paratenon has 2 layers: a superficial layer called the peritenon, which is connected with the underlying layer via the mesotenon; and a deeper layer, surrounding and in direct contact with the epitenon.<sup>24</sup> The sensory supply of the AT derives from the nerves of the attaching muscles and cutaneous nerves, in particular the sural nerve.<sup>25</sup> Moreover, the AT blood supply is guaranteed proximally by the musculotendinous junction, along its length by the surrounding connective tissue, and distally by the bone-tendon junction.<sup>26</sup> The site of AT rupture is usually 2 to 6 cm proximal to the tendon insertion. The poor vascularity in the main body of the AT may play an important role in the pathogenesis of the rupture.<sup>27</sup> Furthermore, the blood flow is higher in women compared with controls, and decreases with aging.<sup>28</sup> Exercise increases the blood flow 4-fold in the AT 5 cm proximal to the insertion, whereas it increases only 2.5-fold 2 cm proximal to the insertion.<sup>29</sup>

## CAUSES AND PATHOLOGY

Several hypotheses have been developed to clarify the causes of AT rupture, but there is no agreement in the literature,<sup>30</sup> and the events leading to an AT rupture are still unclear.<sup>31–33</sup> Numerous factors such as gastrocnemius-soleus dysfunction, a suboptimally conditioned musculotendinous unit, age, gender, changes in training pattern, poor technique, previous injuries, footwear,<sup>34,35</sup> poor tendon vascularity, and degeneration<sup>36,37</sup> are frequently attributed to AT ruptures. In addition, various pathologic conditions, such as infectious diseases, neurologic conditions,<sup>38</sup> hyperthyroidism, renal insufficiency, arteriosclerosis,<sup>39</sup> inflammatory and autoimmune conditions,

hyperuricemia, genetically determined collagen abnormalities,<sup>40</sup> and high serum lipid concentration,<sup>41,42</sup> can be associated with AT ruptures.

Two main theories are proposed for the cause of AT ruptures: the degenerative theory and the mechanical theory. The degenerative theory states that the chronic degeneration of the tendon leads to a rupture without excessive loads being applied. The degeneration of the tendon tissue can be caused by numerous factors such as chronic overloading or microtrauma, physiologic alterations in the tendon, and pharmacologic treatments.

### ***Degenerative Theory***

The molecular events leading to a rupture of the AT are still unclear.<sup>31–33</sup> Arner and colleagues<sup>43</sup> were the first to observe degenerative changes in all of their patients with AT rupture. They hypothesized that these changes were already present before the rupture, although their data were obtained more than 2 days after the rupture. Davidsson and Salo<sup>44</sup> found degenerative changes in 2 patients with AT rupture operated on the day of injury, and they also concluded that the degenerative changes were already present before the rupture.<sup>45</sup> Similar findings were obtained in our own series. In all of the ATs operated on within 24 hours after the injury, we detected marked degenerative changes and collagen disruption.<sup>46,47</sup> Moreover, several investigators observed degenerative alterations in the intratendinous substance of the AT in various patients with a spontaneous rupture, in all sites studied, and most of these abnormalities had no known cause.<sup>47</sup> Several investigators have hypothesized that alterations in blood flow with subsequent hypoxia and impaired metabolism were important factors for the development of the degenerative changes of the AT. Kannus and Jozsa<sup>48</sup> evaluated patients with spontaneous AT ruptures using biopsy specimens, harvested at the time of repair. They noted that only a small proportion of the patients presented symptoms before the rupture, suggesting that degenerative changes are common in the tendons of people who are older than 35 years, and that these changes can be associated with spontaneous rupture.<sup>48</sup> These observations were confirmed by another study of ours. In the 176 AT ruptures that we treated from January 1990 to December 1996, only 9 (5%) patients had had previous symptoms.<sup>49</sup> We also showed that tenocytes from ruptured and tendinopathic tendons produced type III collagen, which alters the physiologic tissue architecture, making the tissue less resistant to high loads and tensile forces.<sup>49</sup> Furthermore, Jozsa and colleagues<sup>50</sup> observed that fibronectin, which is normally located in basement membranes, was present on the torn surfaces of ruptured ATs. Fibronectin is present in a soluble form in plasma, and binds more readily to denatured collagen than to normal collagen, indicating pre-existing collagen denaturation.<sup>51</sup>

### ***Mechanical Theory***

The AT can be damaged when frequent and repetitive microtrauma occur, without leaving enough time to the tendon for repair,<sup>52,53</sup> even in healthy tendons with no degeneration.<sup>54</sup> Numerous movements occurring in many sports, and not just those that require rapid push-off, may be responsible for these occurrences. A healthy AT usually ruptures after a violent muscular strain in the presence of an incomplete synergism of agonist muscle contractions, inefficient action of the plantaris muscle acting as a tensor of the AT, and a discrepancy in the thickness quotient between muscle and tendon.<sup>54</sup> Inglis and Sculco<sup>34</sup> suggested that uncoordinated muscle contractions could cause a rupture of an otherwise normal tendon, and athletes who have a long period of inactivity and return to training too early seem to present a greater risk of a rupture caused by this mechanism. Sporting activity plays a major

role in the development of problems with the AT, especially when training sessions are wrongly performed.<sup>35</sup> Moreover, the risk of rupture of the AT is greatly increased during inversion or eversion movements of the subtalar joint when they are associated with the application of oblique stress. AT injury may also result from structural or dynamic disturbances in normal lower leg mechanics such as functional overpronation, gastrocnemius/soleus insufficiency, overtraining, and repeated microtrauma produced by the eccentric loading of fatigued muscle.<sup>55</sup> In conclusion, complete rupture of the AT can be considered as the consequence of multiple microtrauma and microruptures that lead to failure of the tendon after reaching a critical point.<sup>56</sup>

### ***Drug-related Tendon Rupture***

---

Drugs such as anabolic steroids and fluoroquinolones cause dysplasia of collagen fibrils, which decreases tendon tensile strength and increases the risk of AT rupture.

Normal and healthy tendons are not usually damaged by intratendinous injection of steroids,<sup>57</sup> whereas systemic and local corticosteroid administration have been widely implicated in tendon rupture.<sup>58,59</sup> Nevertheless, numerous studies have shown that the intratendinous or peritendinous injection of corticosteroids into an injured tendon may precipitate a rupture.<sup>57,60</sup> In addition, the analgesic properties of corticosteroids may mask or delay the onset of the symptoms related to damage to the tendon,<sup>61</sup> inducing individuals to maintain their high activity levels even when the tendon is damaged. Corticosteroids also interfere with the healing of tendons, resulting in collagen necrosis. The consequent restoration of tendon strength is attributable to the formation of a cellular amorphous mass of collagen, and, for these reasons, vigorous physical activity should be avoided for at least 2 weeks following injection of corticosteroids close to a tendon.<sup>62</sup>

The administration of the fluoroquinolone (4-quinolone) antibiotics or ciprofloxacin has been associated with tendon rupture. Pefloxacin, ofloxacin, levofloxacin, norfloxacin, and ciprofloxacin are the fluoroquinolones most frequently associated with tendon disorders. A variety of laboratory evidence for the direct deleterious effects of fluoroquinolones on tenocytes has been produced.<sup>63</sup> In a study conducted on 100 patients taking fluoroquinolones, several tendon disorders were observed, including 31 ruptures.<sup>64</sup> However, numerous patients in this study also received corticosteroids. In addition, in an animal study the administration of fluoroquinolone was associated with disruption of the ECM of cartilage, depletion of collagen, and necrosis of chondrocytes, suggesting that these abnormalities in animals might also occur in humans.<sup>65</sup>

### ***Mechanism of Rupture***

---

According to Arner and Lindholm,<sup>66</sup> the mechanisms of AT rupture can be classified into 3 main categories:

1. Fifty-three percent of ruptures occur during weight bearing with the forefoot pushing off and the knee in extension. Sprint starts and jumping sports more often require these movements and this explains the prevalence of left AT rupture in right-handed people.
2. Seventeen percent of ruptures occur following sudden unexpected dorsiflexion of the ankle, such as slipping into a hole, or falling downstairs.
3. In 10% of patients, the tendon was ruptured because of violent dorsiflexion of a plantarflexed foot, such as may occur after falling from a height. In the rest of their patients, they could not identify the mechanism of injury.

## PRESENTATION AND DIAGNOSIS

The diagnosis of AT ruptures should start with a careful assessment of the history followed by physical examination.<sup>38,67</sup> Nevertheless, 20% to 25% of AT ruptures are not diagnosed by the first examining doctor,<sup>11,68,69</sup> whereas the clinical diagnosis is immediate in case of acute ruptures of the AT.

Patients with ruptured ATs usually report a history of pain in the affected leg and the feeling that, at the time of injury, they had been kicked in the posterior aspect of the lower leg. Moreover, the inability to bear weight and weakness or stiffness of the affected ankle are common. However, a small number of patients may be still able to use the flexor hallucis longus, flexor digitorum longus, tibialis posterior, and peroneal tendons to plantarflex the affected ankle.

On clinical examination, diffuse edema and bruising are usually present, and, unless the swelling is severe, a palpable gap may be felt along the course of the tendon, most frequently 2 to 6 cm proximal to the insertion of the tendon.<sup>70</sup> Inspection and palpation should be followed by other tests to confirm the diagnosis, such as the Simmonds and Matles test and the O'Brien and Copeland tests.

The Simmonds or Thompson calf squeeze test is performed with the patient prone on the examination couch and the ankles off the couch, and the examiner squeezes the fleshy part of the calf. This procedure causes the overlying of the AT, producing plantar flexion of the ankle if the tendon is intact.<sup>71</sup> The clinical findings on the affected leg following this test should be compared with the opposite leg to exclude any false positive that may occur in the presence of an intact plantaris tendon.<sup>72</sup>

The Matles test is performed with the patient prone on the examination couch. Patients are asked to flex their knees to 90°, and, if the foot on the affected side falls into neutral or dorsiflexion position, an AT rupture is diagnosed.<sup>73</sup>

The O'Brien test consists of the insertion of a hypodermic 25-gauge needle through the skin of the calf, medial to the midline and 10 cm proximal to the superior border of the calcaneus, within the substance of the tendon. The ankle is then alternately plantarflexed and dorsiflexed and if, on dorsiflexion, the needle point moves distally, the tendon is presumed to be intact in the portion distal to the needle. If, on dorsiflexion, the needle point moves proximally or remains still, there is presumed to be a loss of continuity between the needle and the site of tendon insertion.<sup>69</sup>

The Copeland test is performed by asking the patient to lie prone with the knee flexed to 90° and a sphygmomanometer cuff positioned around the bulk of the calf of the affected leg. The cuff is then inflated to 100 mm Hg with the foot in plantarflexion. The foot is then dorsiflexed. If the pressure increases to approximately 140 mm Hg, the musculotendinous unit is presumed to be intact. The opposite leg should be used to exclude a false-positive response or for comparison purposes.<sup>74</sup>

## IMAGING EVALUATION

Real-time high-resolution ultrasonography and magnetic resonance imaging are more sensitive and less invasive imaging evaluations than soft tissue radiography or xeroradiography. However, ultrasonography is generally considered the primary imaging method for the diagnosis of AT ruptures.<sup>75,76</sup>

Lateral radiographs of the ankle can be performed to diagnose an AT rupture. The loss of normal configuration of the Kager triangle, the space between the anterior aspect of the AT, the posterior aspect of the tibia, and the superior aspect of the calcaneum, is pathognomonic of AT rupture. Arner and colleagues<sup>43</sup> found that deformation of the contours of the distal segment of the tendon resulting from loss of tone were the radiographic changes most likely to be associated with AT rupture. The Toygar sign<sup>77</sup>

involves measuring the angle of the posterior skin surface curve seen on plain radiographs, because the ends of the tendon are displaced anteriorly following a complete tear. The posterior aspect of the Kager triangle then approaches the anterior aspect, and the triangle decreases or disappears. An angle of 130° to 150° indicates AT rupture.

Ultrasonography of the AT is considered the primary imaging method to diagnose a rupture, although it is operator dependent.<sup>75,76</sup> The possibility of performing a dynamic and panoramic evaluation of the AT by means of linear ultrasonography is influenced by the type of transducer used and the angle of the ultrasound beam with respect to the tendon.<sup>78</sup> Moreover, ultrasonography can be used to evaluate the tendon structure after any kind of operative repair. Despite their short focusing distance, high-frequency probes of 7.5 to 10 MHz provide the best resolution.<sup>79</sup> To avoid artifacts during the ultrasonography evaluation of the AT, the probe should be managed by expert examiners and held at right angles to the tendon. Linear array transducers are therefore more suitable than sector-type transducers, which produce excess obliquity of the ultrasound beam at the edges. It may also be necessary to use a synthetic gel spacer or standoff pad, increasing the definition of the surface echoes and allowing a suitable support.<sup>80,81</sup> The normal ultrasonography appearance of the AT is a ribbonlike hypoechogenic image, contained within 2 hyperechogenic bands. Tendon fascicles appear as alternate hypoechogenic and hyperechogenic bands that are more compact when the tendon is strained and more separated when the tendon is relaxed.<sup>80</sup> The presence of an acoustic vacuum with thick, irregular edges is typical in AT rupture.<sup>80</sup>

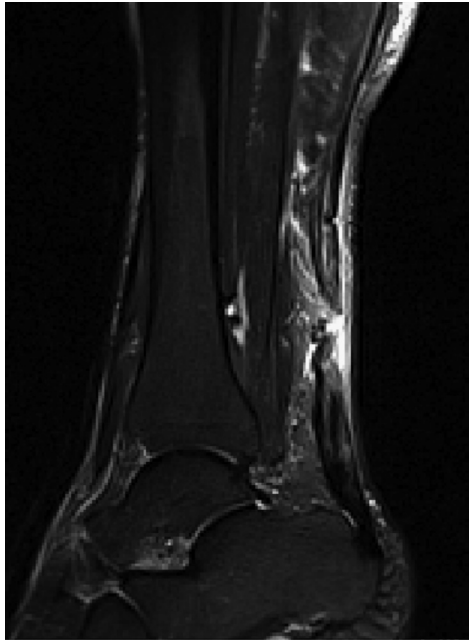
The normal aspect of the AT in magnetic resonance imaging is hypointense on all pulse sequences. The Kager triangle, which appears hyperintense because of the presence of fat, is well delineated by the AT. Sagittal-plane and axial-plane T1-weighted and T2-weighted images are usually used to evaluate suspected AT ruptures, especially in cases of increase in intratendinous signal intensity (**Fig. 1**). In T1-weighted images, the AT rupture appear as disruption of the signal within the tendon, whereas in T2-weighted images the rupture is seen as a generalized increase in signal intensity. Moreover, in T2-weighted images, the edema and hemorrhage at the site of rupture are seen as an area of high signal intensity.

## MANAGEMENT OF ACUTE AT RUPTURE

The management of acutely ruptured AT can be broadly classified into operative and nonoperative<sup>82</sup> and usually depends on the preference of the surgeon and the patient. The surgical management consists of open or percutaneous repair, whereas the conservative management consists of immobilization or functional bracing. More evidence is available for the use of percutaneous techniques than for open surgery,<sup>83,84</sup> and also for the use of early mobilization.<sup>85–87</sup>

Surgical treatment has been the method of choice in the last 2 decades, especially in athletes and young people and in cases of delayed ruptures, whereas conservative, nonoperative management can be used in nonathletes.<sup>88</sup> Open operative management of acute AT ruptures significantly reduces the risk of rerupture compared with nonoperative treatment, but is associated with a significantly higher risk of wound healing problems,<sup>89</sup> which can be reduced by performing surgery percutaneously.<sup>82,83</sup>

The objective of the management of AT rupture is to minimize the morbidity of the injury, optimize rapid return to full function, and prevent complications. The complications can be rated as major or minor from their impact on daily life activities, and can be divided into 3 categories: (1) wound complications, (2) general complications; and



**Fig. 1.** Magnetic resonance imaging showing a complete AT rupture, identifying disruptions of the signal within the tendon.

(3) rerupture. Deep venous thrombosis, pulmonary embolism, and rerupture are the most severe complications and may affect patients regardless of treatment.<sup>89</sup>

### NONOPERATIVE MANAGEMENT

Conservative management and percutaneous repair can be considered viable alternatives to open surgery, which is the most risky and costly of the 3 options.<sup>82</sup> The choice of the type of management should take into account the age, occupation, and level of sporting activity of each patient.

Pels Leusden was the first to propose nonoperative management for AT rupture, in the early 1900s.<sup>90</sup> Immobilization in a below-knee plaster cast in gravity equinus position for 4 weeks followed by a more neutral position for a further 4 weeks is considered the most common nonoperative protocol of management of AT rupture.<sup>91–96</sup> Other investigators maintained the gravity equinus position for 2 weeks, followed by a more neutral position for a further 2 weeks. After this period, a below-knee plaster cast with the foot plantigrade is applied for a further 2 weeks, allowing weight bearing for the last 2 weeks of this management regime. After 1 to 3 weeks of immobilization, braces, splints, or shoes with limitation of dorsiflexion and increased heel height have been used for functional rehabilitation.<sup>97–100</sup> The reports on early functional treatment suggest good functional outcome and low rerupture rates.<sup>101</sup>

In elderly patients, more than 70 years of age, who present chronic AT rupture, physiotherapy alone can be used. These patients usually complain of weakness in plantar flexion and of a strange gait, but they often adapt well to their disability.

Following immobilization, a profound alteration of muscle morphology and physiology occur.<sup>102</sup> Aside from the gastrocnemius muscle, which is a biarticular muscle

able to move when a short leg cast is used, the soleus muscle is particularly susceptible to immobilization. Because of the presence of a high proportion of type I muscle fibers in the human soleus, it is particularly susceptible to atrophy if immobilized.<sup>103</sup> Problems caused by immobilization may also occur after open operative management, but not to the same extent as with nonoperative management. The calf circumference greatly decreases after nonoperative management compared with operative management.<sup>104</sup> Moreover, following operative management, no significant difference of calf circumference is seen compared with the uninjured contralateral tendon.<sup>104</sup> However, patients with open operative repairs spend less time in plaster, and are more often serious athletes who comply well with postoperative management (Fig. 2).

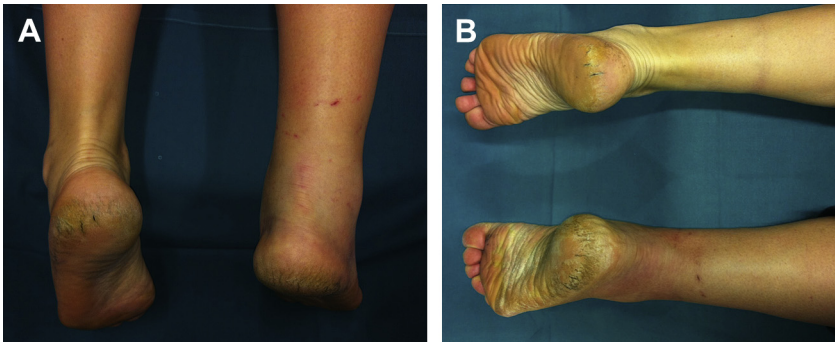
### **Immobilization**

Plaster cast immobilization, usually for a period of 6 to 10 weeks, is most commonly used,<sup>105</sup> and the clinical outcome is comparable with operative management.<sup>94,106</sup> Although function following nonoperative repair is generally good, the high incidence of rerupture is considered unacceptable. Lea and Smith<sup>94</sup> reported a rerupture rate of 13% in 55 spontaneously ruptured ATs, managed with below-the-knee cast immobilization for 8 weeks with the foot in gravity equinus, followed by a 2.5-cm heel lift for a further 4 weeks after cast removal. Persson and Wredmark<sup>96</sup> reported a 35% rate of rerupture in 20 patients managed nonoperatively. Moreover, at the final follow-up, 16 patients had no complaints, the remaining 4 had only minor problems, and 7 patients, not necessarily those whose tendon had reruptured, were not satisfied with the result. Using functional bracing, McComis and colleagues<sup>98</sup> nonoperatively treated 15 patients who had sustained a rupture of the AT. Good functional results were achieved in all patients, suggesting that, in selected cases, functional bracing may be a viable alternative to the use of plaster cast or operative intervention for the management of acute ruptures of the AT.

## **SURGICAL MANAGEMENT**

### **Percutaneous Repair**

In 1977, Ma and Griffith<sup>107</sup> were the first to propose percutaneous repair for the management of AT ruptures, to find a compromise between open surgical and nonsurgical management. After producing 6 small stab incisions across the medial and lateral borders of the tendon, they passed a suture through the tendon using



**Fig. 2.** (A, B) Ruptures of the AT and results after conservative treatment with cast.



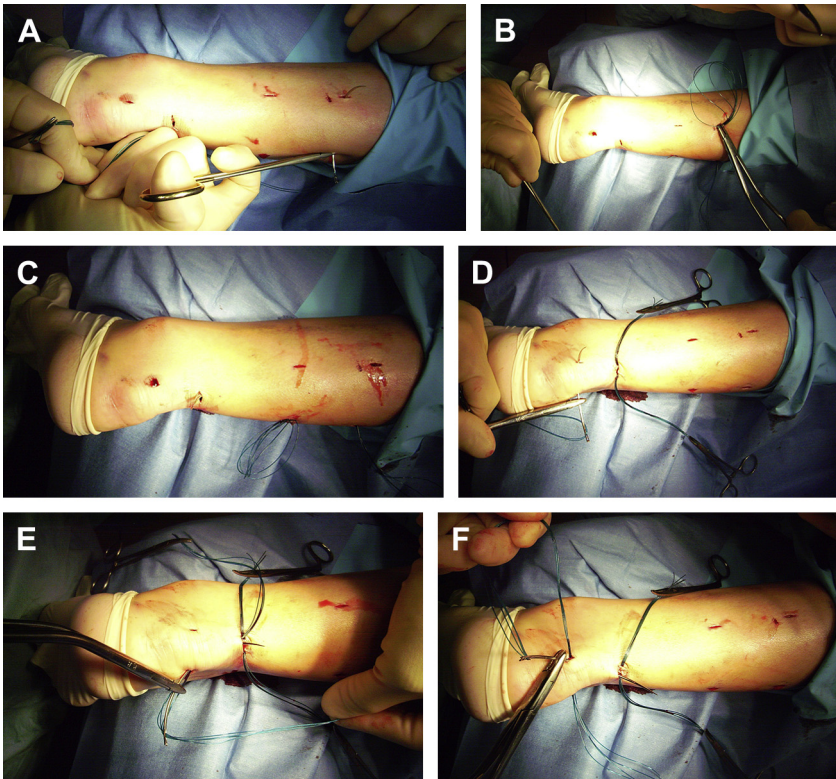
these incisions. There were no reruptures, but 2 minor, noninfectious skin complications occurred. Similar results were obtained by FitzGibbons and colleagues<sup>108</sup> concerning rerupture rate; no skin infections occurred, but there was a case of sural nerve injury. In our previous center in Aberdeen, United Kingdom, Rowley and Scotland<sup>109</sup> described 24 patients with rupture of the AT, 14 treated by casting in equinus position alone, and 10 treated by percutaneous repair. One patient with percutaneous repair suffered entrapment of the sural nerve, but no other complications were encountered. Moreover, patients in the sutured group reached earlier normal plantar flexion strength and normal activity than the group treated by cast alone. In contrast, numerous investigators report a lower success rate with percutaneous repair. Klein and colleagues<sup>110</sup> reported sural nerve entrapment in 13% of 38 patients. Hockenbury and Johns<sup>111</sup> performed an *in vitro* study using a transverse tenotomy of the ATs extracted from 10 fresh frozen below-the-knee cadaver specimens who received percutaneous AT repair or open AT repair. The specimens were divided into 2 groups of 5 specimens each, 1 receiving open Achilles repair using a Bunnell suture technique, the other undergoing percutaneous repair according to the Ma and Griffith<sup>107</sup> technique. The ATs undergoing open repair were able to resist almost twice the amount of ankle dorsiflexion than those undergoing percutaneous repair before a 10-mm gap in the repaired tendon appeared (27.6° vs 14.4°,  $P < .05$ ). In addition, entrapment of the sural nerve occurred in 3 of 5 specimens undergoing percutaneous repair and the tendon stumps were malaligned in 4 of 5 specimens. Since this study, percutaneous repair of AT ruptures has been associated with approximately 50% of the initial strength guaranteed by open repair, and places the sural nerve at higher risk for injury. Furthermore, in most studies, percutaneous repair is associated with a higher rerupture rate compared with open operative repair.<sup>112</sup> Also, high rates of transfixion of the sural nerve have been reported,<sup>109,111</sup> with persistent paresthesias and the necessity of formal exploration to remove the suture and free the nerve.<sup>110</sup>

In 2005, Webb and Bannister<sup>113</sup> described a new percutaneous repair technique, performed under local anesthesia using 3 midline transverse 2.5-cm incisions over the posterior aspect of the AT. No reruptures or sural nerve injuries occurred at a median interval of 35 months after the injury. We later modified this technique using stronger absorbable sutures and a Kessler suture,<sup>114</sup> and Carmont and Maffulli<sup>115</sup> presented a modification of the previously described technique. This modification, which uses 3 transverse incisions, minimizes the chance of sural nerve injury, allowing an even less invasive approach to the tendon that permits the accurate apposition of the tendon ends. Ismail and colleagues<sup>116</sup> compared the mechanical properties of the Achillon mini-incision technique with the long-established Kessler method, concluding that the strength of the repair was related to tendon diameter and that there were no differences between the two techniques. We prefer the Carmont and Maffulli<sup>115</sup> technique compared with the Achillon repair: the first procedure is cheaper, and creates a stronger repair, because it allows the use of a greater number of suture strands (8) for the repair of the AT. However, we conducted a biomechanical study comparing the primary stability of Achillon repair and our modified percutaneous repair<sup>115</sup> on 18 (9 matched pairs) frozen ovine ATs, concluding that the Achillonlike configuration and the modified percutaneous repair of ruptured AT provided similar biomechanical performance.<sup>117</sup>

Despite the high risk of skin wound problems, several advantages are associated with open surgical repair of AT ruptures, such as correct alignment of the torn tendon, excellent functional results with less chance of rerupture, superior strength, and early active mobilization.

### ***Percutaneous Repair Preferred by the Authors***

The patient's position is prone (**Fig. 3**).<sup>115</sup> A 20-mL solution of 1% lignocaine is used to infiltrate the areas 4 to 6 cm proximal and distal to the palpable tendon defect and the skin over the lesion. Ten milliliters of Chirocaine 0.5% are infiltrated deep to the tendon defect. A calf tourniquet is applied to exsanguinate the limb. The skin preparation and draping are performed in a standard fashion. A size 11 blade is used to perform a 1-cm transverse incision over the defect and 4 longitudinal stab incisions are made on the lateral and medial aspects of the AT, 4 and 6 cm proximally to the palpable defect. In addition, 2 longitudinal incisions on either side of the tendon aspect are made proximally to the calcaneal insertion of the tendon. The tendon is then mobilized from the subcutaneous tissue by means of forceps. A 9-cm Mayo needle (BL059N, #B00 round-point spring eye, B. Braun, Aesculap, Tuttlingen, Germany) is threaded with 2 double loops of number 1 Maxon (Tyco Healthcare, Norwalk, CT), and this is passed transversely between the proximal stab incisions through the bulk of the tendon. The



**Fig. 3.** (A) A 9-cm Mayo needle (BL059N, #B00 round-point spring eye, B. Braun, Aesculap, Tuttlingen, Germany) is threaded with 2 double loops of number 1 Maxon (Tyco Healthcare, Norwalk, CT), and is passed transversely between the proximal stab incisions through the bulk of the tendon. (B, C) Each of the ends is then passed distally from just proximal to the transverse Maxon passage through the bulk of the tendon to pass out of the diagonally opposing stab incision. (D) Another double loop of Maxon is passed between the distal stab incisions through the tendon and (E, F) in turn through the tendon and out of the transverse incision starting distal to the transverse passage.

bulk of the tendon is superficial. The loose ends are held with a clip. In turn, each of the ends is then passed distally from just proximal to the transverse Maxon passage through the bulk of the tendon to pass out of the diagonally opposing stab incision. A subsequent diagonal pass is then made to the transverse incision over the ruptured tendon. Clips are used to hold both ends of the Maxon, preventing entanglement. To test the security of this suture, both ends of the Maxon are pulled distally. In addition, the distal stab incision through the tendon is used to pass another double loop of Maxon, and in turn through the tendon and out of the transverse incision starting distal to the transverse passage. The ankle is held in full plantar flexion, and in turn opposing ends of the Maxon thread are tied together with a double throw knot, and then 3 further throws, before being buried using forceps. To maintain the tension of the suture, another clip is used to hold the first throw of the lateral side. The transverse incision is closed with a subcuticular Biosyn suture 3.0 (Tyco Healthcare) and Steri-strips (3M Health Care, St Paul, MN) are used to close the stab incisions. At the end, a Mepore dressing (Molnlycke Health Care, Gothenburg, Sweden) is applied, and a bivalved removable scotch cast with Velcro straps is used to position the foot in full plantar flexion.

### Open Surgical Repair

In recent years, open surgical repair was considered the gold standard for the management of AT ruptures in young, fit individuals (Fig. 4). Moreover, the numerous advances in surgical techniques, such as in postoperative rehabilitation protocols, have encouraged many surgeons to favor direct tendon repair.<sup>39</sup> In addition, the excellent results of surgical repair concerning rerupture rates and tendon strength, such as calf trophism, may help many athletes to return to preinjury physical activities.

Different operative techniques can be performed to repair ruptured ATs, ranging from simple end-to-end suturing by Bunnell or Kessler sutures, to more complex repairs using fascial reinforcement or tendon grafts,<sup>118</sup> artificial tendon implants, materials such as absorbable polymer-carbon fiber composites,<sup>119</sup> xenograft ECM scaffolds,<sup>120,121</sup> Marlex mesh, and collagen tendon prostheses.<sup>122</sup> Primary augmentation of the repair with the plantaris tendon,<sup>123</sup> a single central or 2 (1 medial, 1 lateral) gastrocnemius fascial turndown flaps,<sup>124</sup> the peroneus brevis tendon,<sup>125</sup> the gracil tendon,<sup>126</sup> the bone-patellar tendon,<sup>127</sup> the bone-quadriceps tendon,<sup>128</sup> the semitendinosus tendon,<sup>129</sup> and the free hamstring tendon transfer<sup>130</sup> was also performed. However, there is no evidence that, in acute AT ruptures, this is better than a nonaugmented end-to-end repair.<sup>131</sup> Platelet-rich plasma (PRP) has also been used alone for the management of chronic AT tendinopathy,<sup>132</sup> or in association with open repair in case of acute AT ruptures (Fig. 5).<sup>133</sup> Randomized control trials that evaluated the role

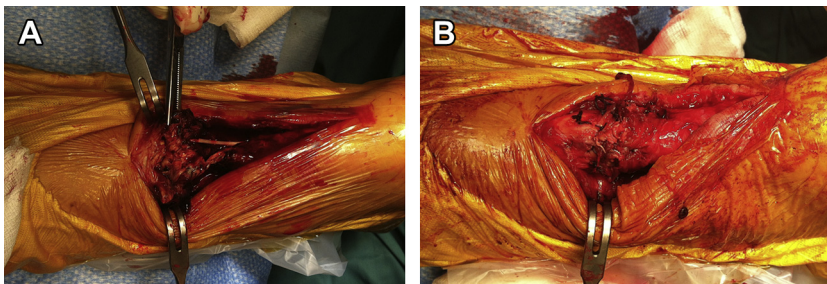
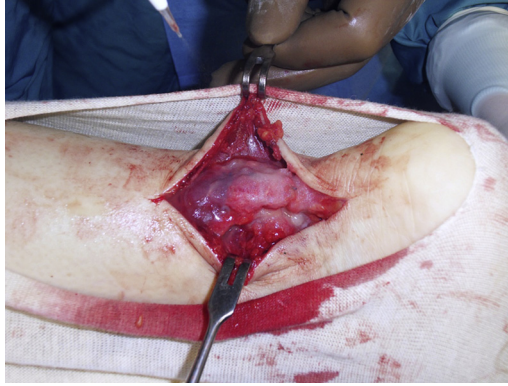

Fig. 4. (A, B) Open surgical repair of an acute AT rupture.



**Fig. 5.** Application of PRP after open surgical repair of an acute AT rupture.

of PRP in acutely ruptured AT or in chronic AT tendinopathy concluded that PRP is not useful for the management of these disorders.<sup>132,133</sup> In our opinion, the use of augmentation should be preferred only when dealing with delayed repairs, chronic tears, and in the management of reruptures.<sup>125,126,134–139</sup>

### POSTOPERATIVE MANAGEMENT

Patients can be discharged 2 days after or the same date as the operation, if any complication occurs. An orthopedic physiotherapist should instruct the patient to use crutches. Patients are allowed to bear weight on the operated leg as tolerated. In addition, it is important to tell the patient to keep the affected leg elevated for as long as possible to prevent swelling. Patients are followed on an outpatient basis at 2-week intervals, and the cast is removed 6 weeks after the operation.<sup>85,86</sup> In case of application of a cast with the ankle in equinus, after this period it is changed, putting the ankle in gradually increasing dorsiflexion, until plantigrade, after 2 and 4 weeks. The cast is then removed 6 weeks after the operation.<sup>140</sup> After the 6-week immobilization period, patients should weight bear partially, and gradual stretching and strengthening exercises are allowed. Full weight bearing is not advised before 8 to 10 weeks after surgery. During the period in the cast, gentle isometric contractions of the gastro-soleus complex must be started, especially after weight bearing has become comfortable. After removal of the cast, patients should start to mobilize the ankle and, after 2 weeks, cycling and swimming are permitted, also continuing the active ankle mobilization exercises. Patients usually return to their normal sports activity 4 months after the surgery.<sup>85–87</sup>

In athletes, postoperative management must be different from that provided for nonathletic patients. The ankle must be immobilized in equinus position with an anterior below-knee plaster-of-Paris slab. Patients are usually discharged on the same day or the day after the operation. They are allowed to toe-touch weight bear on the operated limb as tolerated. They are also advised to keep the operated leg elevated for as long as possible, to reduce postoperative swelling. After 48 to 72 hours, when the postoperative swelling should be significantly reduced, patients are seen in the plaster room to change the plaster-of-Paris slab with an anterior below-knee synthetic slab with the ankle in gravity equinus. The slab is kept in place by an elastic bandage, which allows plantar flexion of the ankle, whereas dorsiflexion is limited by the foot piece of the slab. Patients must use crunches and are allowed to weight bear as tolerated. The slab is changed at the second postoperative week so that the ankle can dorsiflex to

neutral, and dorsiflexion is limited until the sixth week, when the slab is removed. When high-level, well-motivated athletes are compliant, they can usually return to some training 6 to 8 weeks after the removal of the anterior slab. The anterior slab can be substituted with a hinged orthosis, which is more expensive than a simple synthetic cast but can be reused. Moreover, free ankle motion after repair of AT provided by a patellar tendon bearing plaster cast with a protecting frame under the foot, allowing weight bearing immediately after surgery, is also safe and associated with satisfactory clinical results.<sup>141</sup> The preinjury level of sporting activity is usually reached 4 months after surgery.<sup>85–87</sup>

## OUTCOME EVALUATION

The variables usually studied after AT rupture are complications to treatment, calf muscle strength, patient satisfaction, endurance, tendon configuration, impact of AT rupture on absence from work, and impact on sports participation. Overall, outcome measurements using 100-point scoring systems have been used.<sup>4,98,142,143</sup> The major limitation to their common use has been that the scores include dynamometry testing, which are not widely available in routine clinical practice.

The AT Total Rupture Score<sup>144</sup> can be a good solution to resolve this problem. It is a patient-reported instrument for measuring outcome after treatment of total AT rupture. It is a self-administered instrument with high clinical usefulness, and it has been suggested for measuring the outcome, related to symptoms and physical activity, after treatment in patients with total AT rupture.

## SUMMARY

In recent decades, the incidence of AT rupture has increased, whereas the evidence for best management is still debated, and several options are still challenging. In elderly or a few selected patients, conservative management and early mobilization achieves excellent results but the associated rerupture rate is not acceptable in young individuals. Open surgery is frequently associated with higher risk of superficial skin breakdown and wound problems, which can be prevented by performing percutaneous repair. Percutaneous repair, performed under local anesthesia and followed by early functional rehabilitation, is becoming increasingly common, and may be considered in selected patients. However, several percutaneous techniques are proposed by different investigators, and there is a lack of appropriate trials that show which of these is the best. More randomized controlled trials are awaited to clarify the issues and disputes discussed in this article.

## REFERENCES

1. Ames PR, Longo UG, Denaro V, et al. Achilles tendon problems: not just an orthopaedic issue. *Disabil Rehabil* 2008;30(20–22):1646–50.
2. Maffulli N, Waterston SW, Squair J, et al. Changing incidence of Achilles tendon rupture in Scotland: a 15-year study. *Clin J Sport Med* 1999;9:157–60.
3. Longo UG, Rittweger J, Garau G, et al. No influence of age, gender, weight, height, and impact profile in Achilles tendinopathy in masters track and field athletes. *Am J Sports Med* 2009;37:1400–5.
4. Thermann H, Frerichs O, Biewener A, et al. Biomechanical studies of human Achilles tendon rupture. *Unfallchirurg* 1995;98:570–5 [in German].
5. Jarvinen TA, Kannus P, Maffulli N, et al. Achilles tendon disorders: etiology and epidemiology. *Foot Ankle Clin* 2005;10:255–66.

6. Moller A, Astron M, Westlin N. Increasing incidence of Achilles tendon rupture. *Acta Orthop Scand* 1996;67:479–81.
7. Schepsis AA, Jones H, Haas AL. Achilles tendon disorders in athletes. *Am J Sports Med* 2002;30:287–305.
8. Landvater SJ, Renstrom PA. Complete Achilles tendon ruptures. *Clin Sports Med* 1992;11:741–58.
9. Longo UG, Ronga M, Maffulli N. Achilles tendinopathy. *Sports Med Arthrosc* 2009;17:112–26.
10. Longo UG, Ronga M, Maffulli N. Acute ruptures of the Achilles tendon. *Sports Med Arthrosc* 2009;17:127–38.
11. Maffulli N. Rupture of the Achilles tendon. *J Bone Joint Surg Am* 1999;81:1019–36.
12. Cummins EJ, Anson BJ, Carr BW, et al. The structure of the calcaneal tendon (of Achilles) in relation to orthopedic surgery. *Surg Gynecol Obstet* 1946;83:107–16.
13. Rufai A, Ralphs JR, Benjamin M. Structure and histopathology of the insertional region of the human Achilles tendon. *J Orthop Res* 1995;13:585–93.
14. Robins SP. Functional properties of collagen and elastin. *Baillieres Clin Rheumatol* 1988;2:1–36.
15. Kader D, Saxena A, Movin T, et al. Achilles tendinopathy: some aspects of basic science and clinical management. *Br J Sports Med* 2002;36:239–49.
16. Maffulli N, Ewen SW, Waterston SW, et al. Tenocytes from ruptured and tendinopathic Achilles tendons produce greater quantities of type III collagen than tenocytes from normal Achilles tendons. An in vitro model of human tendon healing. *Am J Sports Med* 2000;28:499–505.
17. Kannus P, Jozsa L, Jarvinnen M. Basic science of tendons. In: Garrett WJ, Speer K, Kirkendall DT, editors. *Principles and practice of orthopaedic sports medicine*. Philadelphia: Lippincott Williams & Wilkins; 2000. p. 21–37.
18. Vailas AC, Pedrini VA, Pedrini-Mille A, et al. Patellar tendon matrix changes associated with aging and voluntary exercise. *J Appl Physiol* 1985;58:1572–6.
19. Langberg H, Skovgaard D, Petersen LJ, et al. Type I collagen synthesis and degradation in peritendinous tissue after exercise determined by microdialysis in humans. *J Physiol* 1999;521(Pt 1):299–306.
20. Denaro V, Ruzzini L, Longo UG, et al. Effect of dihydrotestosterone on cultured human tenocytes from intact supraspinatus tendon. *Knee Surg Sports Traumatol Arthrosc* 2010;18:971–6.
21. Knobloch K, Schreibermueller L, Longo UG, et al. Eccentric exercises for the management of tendinopathy of the main body of the Achilles tendon with or without an AirHeel brace. A randomized controlled trial. B: Effects of compliance. *Disabil Rehabil* 2008;30:1692–6.
22. Knobloch K, Schreibermueller L, Longo UG, et al. Eccentric exercises for the management of tendinopathy of the main body of the Achilles tendon with or without the AirHeel brace. A randomized controlled trial. A: effects on pain and microcirculation. *Disabil Rehabil* 2008;30:1685–91.
23. Longo UG, Oliva F, Olivia F, et al. Oxygen species and overuse tendinopathy in athletes. *Disabil Rehabil* 2008;30:1563–71.
24. Kvist H, Kvist M. The operative treatment of chronic calcaneal paratenonitis. *J Bone Joint Surg Br* 1980;62:353–7.
25. Stilwell DL Jr. The innervation of tendons and aponeuroses. *Am J Anat* 1957;100:289–317.

26. Carr AJ, Norris SH. The blood supply of the calcaneal tendon. *J Bone Joint Surg Br* 1989;71:100–1.
27. Astrom M, Westlin N. Blood flow in chronic Achilles tendinopathy. *Clin Orthop Relat Res* 1994;166–72.
28. Schmidt-Rohlfing B, Graf J, Schneider U, et al. The blood supply of the Achilles tendon. *Int Orthop* 1992;16:29–31.
29. Langberg H, Bulow J, Kjaer M. Blood flow in the peritendinous space of the human Achilles tendon during exercise. *Acta Physiol Scand* 1998;163:149–53.
30. Maffulli N, Irwin AS, Kenward MG, et al. Achilles tendon rupture and sciatica: a possible correlation. *Br J Sports Med* 1998;32:174–7.
31. Karousou E, Ronga M, Vigetti D, et al. Collagens, proteoglycans, MMP-2, MMP-9 and TIMPs in human Achilles tendon rupture. *Clin Orthop Relat Res* 2008;466:1577–82.
32. Campani R, Bottinelli O, Genovese E, et al. The role of echotomography in sports traumatology of the lower extremity. *Radiol Med* 1990;79:151–62 [in Italian].
33. Carden DG, Noble J, Chalmers J, et al. Rupture of the calcaneal tendon. The early and late management. *J Bone Joint Surg Br* 1987;69:416–20.
34. Inglis AE, Sculco TP. Surgical repair of ruptures of the tendo Achillis. *Clin Orthop Relat Res* 1981;160–9.
35. Clain MR, Baxter DE. Achilles tendinitis. *Foot Ankle* 1992;13:482–7.
36. Maffulli N. Achilles tendon rupture. *Br J Sports Med* 1995;29:279–80.
37. Williams JG. Achilles tendon lesions in sport. *Sports Med* 1993;16:216–20.
38. Maffulli N. Clinical tests in sports medicine: more on Achilles tendon. *Br J Sports Med* 1996;30:250.
39. Myerson MS. Achilles tendon ruptures. *Instr Course Lect* 1999;48:219–30.
40. Dent CM, Graham GP. Osteogenesis imperfecta and Achilles tendon rupture. *Injury* 1991;22:239–40.
41. Mathiak G, Wening JV, Mathiak M, et al. Serum cholesterol is elevated in patients with Achilles tendon ruptures. *Arch Orthop Trauma Surg* 1999;119:280–4.
42. Ozgurtas T, Yildiz C, Serdar M, et al. Is high concentration of serum lipids a risk factor for Achilles tendon rupture? *Clin Chim Acta* 2003;331:25–8.
43. Arner O, Lindholm A, Orell SR. Histologic changes in subcutaneous rupture of the Achilles tendon; a study of 74 cases. *Acta Chir Scand* 1959;116:484–90.
44. Davidsson L, Salo M. Pathogenesis of subcutaneous tendon ruptures. *Acta Chir Scand* 1969;135:209–12.
45. Jozsa L, Kannus P, Balint JB, et al. Three-dimensional ultrastructure of human tendons. *Acta Anat (Basel)* 1991;142:306–12.
46. Jarvinen M, Jozsa L, Kannus P, et al. Histopathological findings in chronic tendon disorders. *Scand J Med Sci Sports* 1997;7:86–95.
47. Jozsa L, Kannus P. Histopathological findings in spontaneous tendon ruptures. *Scand J Med Sci Sports* 1997;7:113–8.
48. Kannus P, Jozsa L. Histopathological changes preceding spontaneous rupture of a tendon. A controlled study of 891 patients. *J Bone Joint Surg Am* 1991;73:1507–25.
49. Waterston SW, Maffulli N, Ewen SW. Subcutaneous rupture of the Achilles tendon: basic science and some aspects of clinical practice. *Br J Sports Med* 1997;31:285–98.
50. Jozsa L, Lehto M, Kannus P, et al. Fibronectin and laminin in Achilles tendon. *Acta Orthop Scand* 1989;60:469–71.

51. Lehto M, Jozsa L, Kvist M, et al. Fibronectin in the ruptured human Achilles tendon and its paratenon. An immunoperoxidase study. *Ann Chir Gynaecol* 1990;79:72–7.
52. Hayes T, McClelland D, Maffulli N. Metasynchronous bilateral Achilles tendon rupture. *Bull Hosp Jt Dis* 2003;61:140–4.
53. Selvanetti A, Cipolla M, Puddu G. Overuse tendon injuries: basic science and classification. *Oper Tech Sports Med* 1997;5:110–7.
54. Barfred T. Experimental rupture of the Achilles tendon. Comparison of various types of experimental rupture in rats. *Acta Orthop Scand* 1971;42:528–43.
55. Clement DB, Taunton JE, Smart GW. Achilles tendinitis and peritendinitis: etiology and treatment. *Am J Sports Med* 1984;12:179–84.
56. Knorzer E, Folkhard W, Geercken W, et al. New aspects of the etiology of tendon rupture. An analysis of time-resolved dynamic-mechanical measurements using synchrotron radiation. *Arch Orthop Trauma Surg* 1986;105:113–20.
57. Matthews LS, Sonstegard DA, Phelps DB. A biomechanical study of rabbit patellar tendon: effects of steroid injection. *J Sports Med* 1974;2:349–57.
58. Newnham DM, Douglas JG, Legge JS, et al. Achilles tendon rupture: an underrated complication of corticosteroid treatment. *Thorax* 1991;46:853–4.
59. Dickey W, Patterson V. Bilateral Achilles tendon rupture simulating peripheral neuropathy: unusual complication of steroid therapy. *J R Soc Med* 1987;80:386–7.
60. Unverferth LJ, Olix ML. The effect of local steroid injections on tendon. *J Sports Med* 1973;1:31–7.
61. DiStefano VJ, Nixon JE. Ruptures of the Achilles tendon. *J Sports Med* 1973;1:34–7.
62. Kennedy JC, Willis RB. The effects of local steroid injections on tendons: a biomechanical and microscopic correlative study. *Am J Sports Med* 1976;4:11–21.
63. Bernard-Beaubois K, Hecquet C, Hayem G, et al. In vitro study of cytotoxicity of quinolones on rabbit tenocytes. *Cell Biol Toxicol* 1998;14:283–92.
64. Royer RJ, Pierfitte C, Netter P. Features of tendon disorders with fluoroquinolones. *Therapie* 1994;49:75–6.
65. Szarfman A, Chen M, Blum MD. More on fluoroquinolone antibiotics and tendon rupture. *N Engl J Med* 1995;332:193.
66. Arner O, Lindholm A. Subcutaneous rupture of the Achilles tendon; a study of 92 cases. *Acta Chir Scand Suppl* 1959;116:1–51.
67. Maffulli N. Current concepts in the management of subcutaneous tears of the Achilles tendon. *Bull Hosp Jt Dis* 1998;57:152–8.
68. Maffulli N. The clinical diagnosis of subcutaneous tear of the Achilles tendon. A prospective study in 174 patients. *Am J Sports Med* 1998;26:266–70.
69. O'Brien T. The needle test for complete rupture of the Achilles tendon. *J Bone Joint Surg Am* 1984;66:1099–101.
70. DiStefano VJ, Nixon JE. Achilles tendon rupture: pathogenesis, diagnosis, and treatment by a modified pullout wire technique. *J Trauma* 1972;12:671–7.
71. Scott BW, al Chalabi A. How the Simmonds-Thompson test works. *J Bone Joint Surg Br* 1992;74:314–5.
72. Simmonds FA. The diagnosis of the ruptured Achilles tendon. *Practitioner* 1957;179:56–8.
73. Matles AL. Rupture of the tendo Achilles. Another diagnostic sign. *Bull Hosp Joint Dis* 1975;36:48–51.
74. Copeland SA. Rupture of the Achilles tendon: a new clinical test. *Ann R Coll Surg Engl* 1990;72:270–1.



75. Bleakney RR, Tallon C, Wong JK, et al. Long-term ultrasonographic features of the Achilles tendon after rupture. *Clin J Sport Med* 2002;12:273–8.
76. Rolf C, Movin T. Etiology, histopathology, and outcome of surgery in achillodynia. *Foot Ankle Int* 1997;18:565–9.
77. Toygar O. Subkutane ruptur der Achillessehne (diagnostik und behandlungsergebnisse). *Helv Chir Acta* 1947;14:209–31.
78. Maffulli N, Dymond NP, Capasso G. Ultrasonographic findings in subcutaneous rupture of Achilles tendon. *J Sports Med Phys Fitness* 1989;29:365–8.
79. Fornage BD. Achilles tendon: US examination. *Radiology* 1986;159:759–64.
80. Barbolini G, Monetti G, Montorsi A, et al. Results with high-definition sonography in the evaluation of Achilles tendon conditions. *Int J Sports Traumatology* 1988;10:225–34.
81. Maffulli N, Dymond NP, Regine R. Surgical repair of ruptured Achilles tendon in sportsmen and sedentary patients: a longitudinal ultrasound assessment. *Int J Sports Med* 1990;11:78–84.
82. Ebinesan AD, Sarai BS, Walley GD, et al. Conservative, open or percutaneous repair for acute rupture of the Achilles tendon. *Disabil Rehabil* 2008;30(20–22):1721–5.
83. Khan RJ, Fick D, Keogh A, et al. Treatment of acute Achilles tendon ruptures. A meta-analysis of randomized, controlled trials. *J Bone Joint Surg Am* 2005;87:2202–10.
84. Longo UG, Ramamurthy C, Denaro V, et al. Minimally invasive stripping for chronic Achilles tendinopathy. *Disabil Rehabil* 2008;30(20–22):1709–13.
85. Maffulli N, Tallon C, Wong J, et al. Early weightbearing and ankle mobilization after open repair of acute midsubstance tears of the Achilles tendon. *Am J Sports Med* 2003;31:692–700.
86. Maffulli N, Tallon C, Wong J, et al. No adverse effect of early weight bearing following open repair of acute tears of the Achilles tendon. *J Sports Med Phys Fitness* 2003;43:367–79.
87. Maffulli N. Immediate weight-bearing is not detrimental to operatively or conservatively managed rupture of the Achilles tendon. *Aust J Physiother* 2006;52:225.
88. Farizon F, Pages A, Azoulai JJ, et al. Surgical treatment of ruptures of the Achilles tendon. Apropos of 42 cases treated by Bosworth's technique. *Rev Chir Orthop Reparatrice Appar Mot* 1997;83:65–9 [in French].
89. Saxena A, Maffulli N, Nguyen A, et al. Wound complications from surgeries pertaining to the Achilles tendon: an analysis of 219 surgeries. *J Am Podiatr Med Assoc* 2008;98:95–101.
90. Stein SR, Luekens CA Jr. Closed treatment of Achilles tendon ruptures. *Orthop Clin North Am* 1976;7:241–6.
91. Edna TH. Non-operative treatment of Achilles tendon ruptures. *Acta Orthop Scand* 1980;51:991–3.
92. Gillies H, Chalmers J. The management of fresh ruptures of the tendo Achillis. *J Bone Joint Surg Am* 1970;52:337–43.
93. Jacobs D, Martens M, Van Audekercke R, et al. Comparison of conservative and operative treatment of Achilles tendon rupture. *Am J Sports Med* 1978;6:107–11.
94. Lea RB, Smith L. Non-surgical treatment of tendo Achillis rupture. *J Bone Joint Surg Am* 1972;54:1398–407.
95. Lildholdt T, Munch-Jorgensen T. Conservative treatment to Achilles tendon rupture. A follow-up study of 14 cases. *Acta Orthop Scand* 1976;47:454–8.
96. Persson A, Wredmark T. The treatment of total ruptures of the Achilles tendon by plaster immobilisation. *Int Orthop* 1979;3:149–52.

97. Saleh M, Marshall PD, Senior R, et al. The Sheffield splint for controlled early mobilisation after rupture of the calcaneal tendon. A prospective, randomised comparison with plaster treatment. *J Bone Joint Surg Br* 1992;74:206–9.
98. McComis GP, Nawoczenski DA, DeHaven KE. Functional bracing for rupture of the Achilles tendon. Clinical results and analysis of ground-reaction forces and temporal data. *J Bone Joint Surg Am* 1997;79:1799–808.
99. Eames MH, Eames NW, McCarthy KR, et al. An audit of the combined non-operative and orthotic management of ruptured tendo Achillis. *Injury* 1997;28:289–92.
100. Thermann H, Hufner T, Tscherne H. Achilles tendon rupture. *Orthopade* 2000;29:235–50 [in German].
101. Wong J, Barrass V, Maffulli N. Quantitative review of operative and nonoperative management of Achilles tendon ruptures. *Am J Sports Med* 2002;30:565–75.
102. Qin L, Appell HJ, Chan KM, et al. Electrical stimulation prevents immobilization atrophy in skeletal muscle of rabbits. *Arch Phys Med Rehabil* 1997;78:512–7.
103. Vrbova G. Changes in the motor reflexes produced by tenotomy. *J Physiol* 1963;166:241–50.
104. Haggmark T, Liedberg H, Eriksson E, et al. Calf muscle atrophy and muscle function after non-operative vs operative treatment of Achilles tendon ruptures. *Orthopedics* 1986;9:160–4.
105. Fierro NL, Sallis RE. Achilles tendon rupture. Is casting enough? *Postgrad Med* 1995;98:145–52.
106. Stein SR, Luekens CA. Methods and rationale for closed treatment of Achilles tendon ruptures. *Am J Sports Med* 1976;4:162–9.
107. Ma GW, Griffith TG. Percutaneous repair of acute closed ruptured Achilles tendon: a new technique. *Clin Orthop Relat Res* 1977;247–55.
108. FitzGibbons RE, Hefferon J, Hill J. Percutaneous Achilles tendon repair. *Am J Sports Med* 1993;21:724–7.
109. Rowley DI, Scotland TR. Rupture of the Achilles tendon treated by a simple operative procedure. *Injury* 1982;14:252–4.
110. Klein W, Lang DM, Saleh M. The use of the Ma-Griffith technique for percutaneous repair of fresh ruptured tendo Achillis. *Chir Organi Mov* 1991;76:223–8.
111. Hockenbury RT, Johns JC. A biomechanical in vitro comparison of open versus percutaneous repair of tendon Achilles. *Foot Ankle* 1990;11:67–72.
112. Bradley JP, Tibone JE. Percutaneous and open surgical repairs of Achilles tendon ruptures. A comparative study. *Am J Sports Med* 1990;18:188–95.
113. Webb JM, Bannister GC. Percutaneous repair of the ruptured tendo Achillis. *J Bone Joint Surg Br* 1999;81:877–80.
114. McClelland D, Maffulli N. Percutaneous repair of ruptured Achilles tendon. *J R Coll Surg Edinb* 2002;47:613–8.
115. Carmont MR, Maffulli N. Modified percutaneous repair of ruptured Achilles tendon. *Knee Surg Sports Traumatol Arthrosc* 2008;16:199–203.
116. Ismail M, Karim A, Shulman R, et al. The Achillon Achilles tendon repair: is it strong enough? *Foot Ankle Int* 2008;29:808–13.
117. Longo UG, Forriol F, Campi S, et al. A biomechanical comparison of the primary stability of two minimally invasive techniques for repair of ruptured Achilles tendon. *Knee Surg Sports Traumatol Arthrosc* 2012;20:1392–7.
118. Soma CA, Mandelbaum BR. Repair of acute Achilles tendon ruptures. *Orthop Clin North Am* 1995;26:239–47.
119. Parsons JR, Rosario A, Weiss AB, et al. Achilles tendon repair with an absorbable polymer-carbon fiber composite. *Foot Ankle* 1984;5:49–53.

120. Wisbeck JM, Parks BG, Schon LC. Xenograft scaffold full-wrap reinforcement of Krackow Achilles tendon repair. *Orthopedics* 2012;35:e331-4.
121. Magnussen RA, Glisson RR, Moorman CT. Augmentation of Achilles tendon repair with extracellular matrix xenograft: a biomechanical analysis. *Am J Sports Med* 2011;39:1522-7.
122. Kato YP, Dunn MG, Zawadsky JP, et al. Regeneration of Achilles tendon with a collagen tendon prosthesis. Results of a one-year implantation study. *J Bone Joint Surg Am* 1991;73:561-74.
123. Quigley TB, Scheller AD. Surgical repair of the ruptured Achilles tendon. Analysis of 40 patients treated by the same surgeon. *Am J Sports Med* 1980;8:244-50.
124. Ponnappala P, Aaranson RR. Reconstruction of Achilles tendon rupture with combined V-Y plasty and gastrocnemius-soleus fascia turndown graft. *J Foot Ankle Surg* 2010;49:310-5.
125. Maffulli N, Spiezia F, Pintore E, et al. Peroneus brevis tendon transfer for reconstruction of chronic tears of the Achilles tendon: a long-term follow-up study. *J Bone Joint Surg Am* 2012;94:901-5.
126. Maffulli N, Spiezia F, Testa V, et al. Free gracilis tendon graft for reconstruction of chronic tears of the Achilles tendon. *J Bone Joint Surg Am* 2012;94:906-10.
127. Miyamoto W, Takao M, Matsushita T. Reconstructive surgery using autologous bone-patellar tendon graft for insertional Achilles tendinopathy. *Knee Surg Sports Traumatol Arthrosc* 2012;20:1863-7.
128. Philippot R, Wegrzyn J, Grosclaude S, et al. Repair of insertional Achilles tendinosis with a bone-quadriceps tendon graft. *Foot Ankle Int* 2010;31:802-6.
129. Sarzaeem MM, Lemraski MM, Safdari F. Chronic Achilles tendon rupture reconstruction using a free semitendinosus tendon graft transfer. *Knee Surg Sports Traumatol Arthrosc* 2012;20:1386-91.
130. Maffulli N, Longo UG, Spiezia F, et al. Free hamstrings tendon transfer and interference screw fixation for less invasive reconstruction of chronic avulsions of the Achilles tendon. *Knee Surg Sports Traumatol Arthrosc* 2010;18:269-73.
131. Jessing P, Hansen E. Surgical treatment of 102 tendo Achillis ruptures- suture or tenoplasty? *Acta Chir Scand* 1975;141:370-7.
132. de Vos RJ, Weir A, van Schie HT, et al. Platelet-rich plasma injection for chronic Achilles tendinopathy: a randomized controlled trial. *JAMA* 2010;303:144-9.
133. Schepull T, Kvist J, Norrman H, et al. Autologous platelets have no effect on the healing of human Achilles tendon ruptures: a randomized single-blind study. *Am J Sports Med* 2011;39:38-47.
134. Maffulli N, Ajs A, Longo UG, et al. Chronic rupture of tendo Achillis. *Foot Ankle Clin* 2007;12:583-96, vi.
135. Maffulli N, Longo UG, Gougoulas N, et al. Ipsilateral free semitendinosus tendon graft transfer for reconstruction of chronic tears of the Achilles tendon. *BMC Musculoskelet Disord* 2008;9:100.
136. Maffulli N, Leadbetter WB. Free gracilis tendon graft in neglected tears of the Achilles tendon. *Clin J Sport Med* 2005;15:56-61.
137. Carmont MR, Maffulli N. Less invasive Achilles tendon reconstruction. *BMC Musculoskelet Disord* 2007;8:100.
138. Maffulli N, Ajs A. Management of chronic ruptures of the Achilles tendon. *J Bone Joint Surg Am* 2008;90:1348-60.
139. Pintore E, Barra V, Pintore R, et al. Peroneus brevis tendon transfer in neglected tears of the Achilles tendon. *J Trauma* 2001;50:71-8.

140. Coutts A, MacGregor A, Gibson J, et al. Clinical and functional results of open operative repair for Achilles tendon rupture in a non-specialist surgical unit. *J R Coll Surg Edinb* 2002;47:753–62.
141. Solveborn SA, Moberg A. Immediate free ankle motion after surgical repair of acute Achilles tendon ruptures. *Am J Sports Med* 1994;22:607–10.
142. Leppilahti J, Forsman K, Puranen J, et al. Outcome and prognostic factors of Achilles rupture repair using a new scoring method. *Clin Orthop Relat Res* 1998;152–61.
143. Moller M, Karlsson J, Lind K, et al. Tissue expansion for repair of severely complicated Achilles tendon ruptures. *Knee Surg Sports Traumatol Arthrosc* 2001;9:228–32.
144. Nilsson-Helander K, Thomee R, Gravare-Silbernagel K, et al. The Achilles tendon total rupture score (ATRS): development and validation. *Am J Sports Med* 2007;35:421–6.